

Right Ventricular Pacing-Induced Heart Failure after Mitral Valve Replacement

Meng-Ta Tsai,¹ Wei-Chuan Tsai,² Jun-Neng Roan¹ and Chwan-Yau Luo^{1,3}

It is an unfortunate fact that pacing-induced heart failure after cardiac surgery is frequently ignored by medical professionals. A 60-year-old woman with chronic atrial fibrillation with a single-lead right ventricular permanent pacemaker for a prolonged ventricular pause underwent mitral valve replacement 6 months later for severe stenosis (NYHA functional class III). The patient's pacing rate was increased from the preoperative level of 60 beats per minute (bpm) to 70 bpm in order to facilitate weaning from the cardiopulmonary bypass. However, her postoperative low cardiac output continued to progress, despite the presence of inotropes. The patient's cold limbs and oliguria persisted until she underwent echocardiographic imaging, which showed dyssynchronous ventricular contraction 29 days post-surgery but which improved after the pacing rate was reduced below her spontaneous rate. Ultimately, clinicians should exercise caution when increasing right ventricular pacing for postoperative stunned myocardium. Due to the problems that can arise from an increased pacing rate, postoperative pacing strategy in patients complicated with low cardiac output after mitral valve replacement merits further discussion.

Key Words: Dyssynchrony • Mitral valve replacement • Right ventricular pacing • Stunned myocardium

INTRODUCTION

External pacing is a common practice after cardiac surgery. Either through use of a temporary epicardial pacing wire or by preexisting permanent pacemaker, surgeons try to overcome postoperative heart block, bradycardia, or low cardiac output by increasing the pacing rate. Although the prevalence of permanent post-surgery pacing ranges from 0.4-6.7%¹ its possible adverse effects are often ignored. Right ventricular (RV) pacing may lead to dyssynchronization of not only atrio-

biventricular contraction, but also to interventricular and intraventricular dyssynchrony and consequent ventricular dysfunction.^{2,3} We present a case of mitral valve replacement (MVR) with a complicated postoperative course due to unrecognized RV pacing-related ventricular dysfunction.

CASE REPORT

A 60-year-old woman with moderate-to-severe mitral stenosis had been followed-up for many years. She had chronic atrial fibrillation, which was complicated with a high-degree atrioventricular block and syncope episodes since 2010. Use of a Holter monitor demonstrated the patient's maximal long pause of 9.89 seconds, and a transvenous single-lead RV permanent pacemaker was implanted. Its pacing rate was set at 60 beats per minute (bpm), and the pacing site was seated on the RV high septum. The ratio of pacing rhythm to

Received: February 27, 2014 Accepted: July 21, 2014

¹Division of Cardiovascular Surgery, Department of Surgery; ²Division of Cardiology, Department of Internal Medicine; National Cheng Kung University Hospital and College of Medicine; ³Cardiovascular Research Center, National Cheng-Kung University, Tainan, Taiwan.

Address correspondence and reprint requests to: Dr. Chwan-Yau Luo, Department of Surgery, National Cheng Kung University Hospital, No. 138, Sheng-Li Road, Tainan 704, Taiwan. Tel: 886-6-235-3535 ext. 5372; Fax: 886-6-209-5968; E-mail: luochwya@mail.ncku.edu.tw

her spontaneous rhythm was approximately 1:1 (Figure 1A). Her diabetes was well-controlled with oral medications, and she continued to suffer the ill-effects of an old stroke with right hemiparesis. However, she remained capable of independently conducting her own activities of daily life.

She was free from syncope and heart failure progression (NYHA class III) until 2011. The echocardiography showed severe mitral stenosis (mitral valve area = 0.68 cm^2), an adequate left ventricular ejection fraction [left ventricular ejection fraction (LVEF) = 68%], and mild tricuspid regurgitation without pulmonary hypertension. Preoperative coronary catheterization showed one-vessel disease in the left anterior descending artery, with 60% stenosis over the proximal segment and 50% stenosis over the orifice of the 1st diagonal branch.

The patient underwent an MVR procedure (a 29-

mm Hancock II porcine heart valve; Medtronic, Minneapolis, MN, USA, was used instead of a mechanical valve because of her request) and coronary artery bypass grafting with the left internal thoracic artery. Both anterior and posterior mitral leaflets and subvalvular apparatus were excised because of extensive calcification. We did not consider a MAZE operation because of the patient's huge left atrium (6 cm) and longstanding chronic atrial fibrillation (AF) (more than 5 years). Myocardial protection was conducted with cold blood cardioplegia and epicardial cooling. The aortic cross-clamp and cardiopulmonary bypass times were 112 and 134 minutes, respectively. She regained atrial fibrillation with a ventricular response of around 60 bpm after an aortic declamp. Despite administration of $14 \mu\text{g/kg/min}$ of dobutamine and $0.01 \mu\text{g/kg/min}$ of epinephrine, transesophageal echocardiography showed that the ventri-

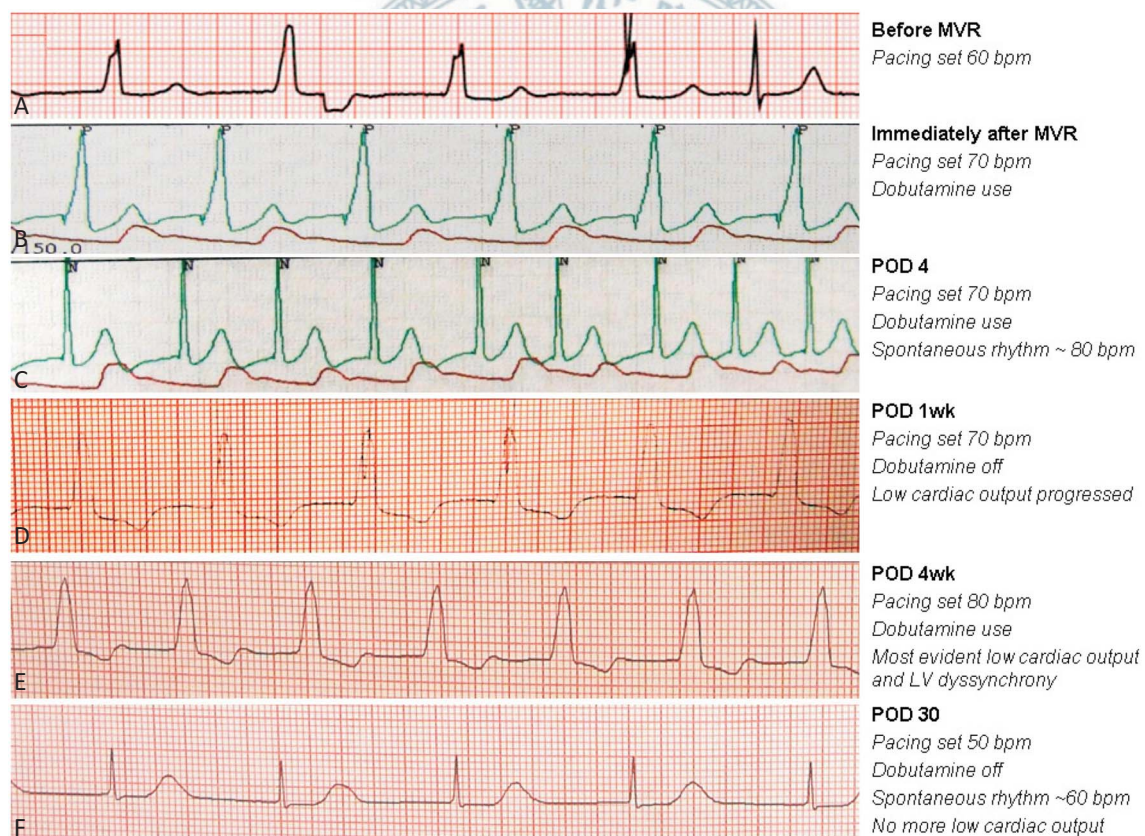


Figure 1. Serial electrocardiographies. (A) Baseline pacing rate of 60 bpm with intermittent spontaneous rhythm. (B) Immediately after MVR her rhythm was totally dependent on pacing of 70 bpm. (C) Under Dobutamine support she regained spontaneous AF rhythm of 80 bpm. (D) After cessation of Dobutamine her spontaneous rate decreased and was dependent on pacing of 70 bpm again. Heart failure was progressing. (E) Pacing was increased to 80 bpm to overcome low cardiac output but in vain. The LV dyssynchrony was most evident at this time. (F) With completely spontaneous AF rhythm around 60 bpm, heart failure dramatically improved. AF, atrial fibrillation; LV, left ventricle; MVR, mitral valve replacement; POD, postoperative day.

cular contraction was globally impaired, which made weaning from the cardiopulmonary bypass difficult. We increased the pacing rate to 70 bpm, and the cardiopulmonary bypass could be weaned off with dobutamine only (Figure 1B). Biventricular epicardial pacing was not considered in this case because it primarily benefits patients with preoperative left ventricle (LV) dysfunction and wide QRS,⁶ which was not the condition of our patient.

The patient's atrial fibrillation with ventricular response recovered to around 80 bpm with dobutamine support on postoperative day 1 (Figure 1C). There was no ST segment change, nor were there any other gatherings or new Q-wave. Her postoperative laboratory data also excluded perioperative myocardial infarction from any differential diagnosis (peak CK-MB level of 21.44 ng/ml, CK 259 ng/ml, and Troponin-T 0.554 ng/ml, all peaked within 2 days after the operation). After inotrope use was discontinued, the patient's rhythm was noted to be totally pacing (70 bpm) (Figure 1D).

It was noted that the patient's low cardiac output had developed during the 7 days subsequent to surgery, with progressing fatigue, cold limbs, and oliguria. Echocardiography excluded cardiac tamponade; in fact the prosthetic valve functioned well. The patient showed global LV hypokinesia (LVEF = 32%) and paradoxical septal motion, a common post-cardiac surgery echocardiographic finding.⁴ We thought that the post-MVR change explained the impaired ventricular function. We added dobutamine and raised the pacing rate to 80 bpm, (Figure 1E) but LVEF further declined (LVEF = 25%). The E/E' of 48 suggested diastolic dysfunction. Besides, dyssynchronous contraction of the LV lateral and septal walls was manifest. The septal-to-posterior wall contraction delay was 340 ms (Figure 2, > 130 ms indicates dyssynchrony⁵). These findings, combined with the timing of the progression of her heart failure, were instrumental in establishing the diagnosis of RV pacing-induced heart failure.

Thereafter, we reduced the pacing rate to 50 bpm. The patient regained complete atrial fibrillation with a ventricular response of 50-60 bpm (Figure 1F). Her LV contraction became synchronous and her heart failure improved dramatically within days (LVEF = 45%). The E/E' gradually decreased to 19, Overall, oliguria

improved and Dobutamine was weaned off. The patient was subsequently discharged on postoperative day 47.

DISCUSSION

Heart failure induced by the uncoupling of the atrioventricular contraction after RV pacing is conventionally described as "Pacemaker syndrome". It has been extended to a broader concept of RV pacing-related ventricular dysfunction to include dyssynchrony of the interventricular and intraventricular contractions.^{2,3} RV pacing propagates electrical signals through myocardium rather than through the His-Purkinje system. It produces a functional conduction delay comparable to left bundle branch block, which leads to dyssynchronous myocardial contraction and subsequent ventricular dysfunction.^{2,3} In this patient with chronic AF, her condition worsened when atrio-ventricular synchrony was originally lost. Additionally, her heart failure was exacerbated by an increased RV pacing rate, which arose due to substantial dyssynchrony at the ventricular level.

Dyssynchrony may be present in up to 50% of patients after RV pacing, but only 26% of them develop heart failure.² When a pacing site is distant from the conduction system, especially the RV apex, it produces more dyssynchrony.³ The RV apex, in fact, seems to be the worst location. Alternatively, the septum (as in our patient), RV outflow tract, or His bundle may be better choices because of their adjacency to the conduction system.³

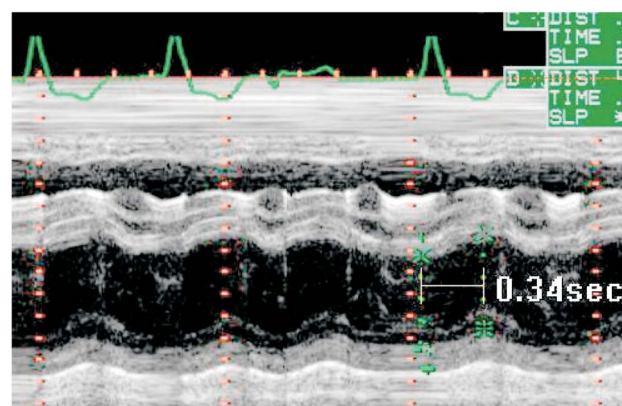


Figure 2. M-mode echocardiography showed a septal-to-posterior contraction delay up to 340 ms.

It has been previously observed that elevated RV pacing yields a higher incidence of ventricular dysfunction, but no clear threshold has been established.³ Patients with myocardial infarction, LVEF < 50%, and QRS latency > 120 ms are at greater risk.³ Our patient had none of these risks, and tolerated an uneventful RV pacing for 6 months. However, she still suffered heart failure after the pacing rate had been increased for only one postoperative week. Apparently, mitral valve surgery could be an important exacerbator.

Mitral annulo-ventricular continuity moderates LV geometry and systolic function.⁶ Preservation of the chordopapillary apparatus during MVR prevents postoperative regional wall-motion abnormality (RWMA) and impairment of LVEF.⁶ In this case, the severe subvalvular calcification made chordal preservation difficult, and the consequently impaired LVEF and RWMA might have accentuated the effect of the RV pacing-related dyssynchrony. We therefore suggest that the mitral chords be preserved as completely as possible in patients requiring a permanent pacemaker. If chordal transection is inevitable, placement of an artificial neo-chord must be considered. If any chordal preservation or reconstruction is unfeasible due to extensive papillary muscle calcification, other options including minimizing RV pacing rate, an alternative pacing site, or biventricular pacing should be considered.^{2,3,7}

The benefits of cardiac resynchronization therapy highlight the drawbacks of isolated RV pacing. Compared with atrio-univentricular pacing, postoperative atrio-biventricular epicardial pacing further increases the cardiac index to 22%, which facilitates weaning from CPB and recovery from postoperative myocardial stunning, especially in patients who have preoperative LV dysfunction and wide QRS.⁷ We did not consider biventricular pacing due to our patient's preoperative condition. However, if chord preservation or reconstruction is impossible and the post-MVR effect on the LVEF and regional wall-motion is encountered, biventricular pacing in patients who require postoperative pacing may be considered because these patients may be more vulnerable to RV pacing-related heart failure, even without preoperative LV dysfunction and wide QRS.

However, RV pacing also leads to diastolic dysfunction, changes in regional perfusion, oxygen demand and myocardial strain, and ventricular remodeling,² which

cannot be completely avoided even with biventricular pacing. Therefore, minimizing unnecessary pacing is of the utmost importance. Regular echocardiographic follow-ups are mandatory after increasing the rate of pacing. Any unexplained deterioration of heart function after increasing the percentage of pacing should merit attention and response. Surgeons must realize that increasing the pacing rate is not always beneficial for overcoming postoperative low cardiac output syndrome.

CONCLUSIONS

RV pacing-induced heart failure is often overlooked in surgical patients. Cardiac surgeons must be vigilant in observing any clinical deterioration after pacemaker adjustments, and aware that increasing the pacing rate alone does not always solve postoperative low cardiac output. In this case, the relationship between chordal transection and RV pacing-related dyssynchrony made us reconsider the chord-preserving and pacing strategy in mitral valve surgery.

CONFLICT OF INTEREST

None declared.

REFERENCES

1. Silvero M, Browne L, Solari G. *Pacemaker following adult cardiac surgery*. In: Min M (Ed.). *Cardiac Pacemakers - Biological Aspects, Clinical Applications and Possible Complications*. Croatia: InTech; 2011:135-60. Available at <<http://www.intechopen.com>>.
2. Tops LF, Schalij MJ, Bax JJ. The effects of right ventricular apical pacing on ventricular function and dyssynchrony implications for therapy. *J Am Coll Cardiol* 2009;54:764-76.
3. Sweeney MO, Prinzen FW. Ventricular pump function and pacing: physiological and clinical integration. *Circ Arrhythm Electrophysiol* 2008;1:127-39.
4. Reynolds HR, Tunick PA, Grossi EA, et al. Paradoxical septal motion after cardiac surgery: a review of 3,292 cases. *Clin Cardiol* 2007;30:621-3.
5. Powell BD, Espinosa RE, Yu CM, Oh JK. *Tissue Doppler imaging, strain imaging, and dyssynchrony assessment*. In: Oh JK, Seward JB, Tajik AJ (Eds). *Echo Manual*, 3rd ed. Lippincott Williams & Wilkins; 2006:91.

6. Chowdhury UK, Venkataiya JK, Patel CD, et al. Serial radionuclide angiographic assessment of left ventricular ejection fraction and regional wall motion after mitral valve replacement in patients with rheumatic disease. *Am Heart J* 2006;152:1201-7.
7. Vaughan P, Bhatti F, Hunter S, Dunning J. Does biventricular pacing provide a superior cardiac output compared to univentricular pacing wires after cardiac surgery? *Interact Cardiovasc Thorac Surg* 2009;8:673-8.

